

Anderson–Fabry disease: an important differential diagnosis in patients with unexplained left ventricular hypertrophy

Perry Elliott

The Heart Hospital, University College, London, UK

Correspondence: Dr Perry Elliott, The Heart Hospital, 16-18 Westmoreland Street, London W1G 8PH, UK.
Tel: +44 207 573 8888; fax: +44 207 573 8838; e-mail: pelliott@doctors.org.uk

Abstract

Anderson–Fabry disease is an X-linked lysosomal storage disorder that results in a deficiency of the enzyme α -galactosidase A. Previously believed to be rare, Anderson–Fabry disease is present in 4–5% of men with unexplained left ventricular hypertrophy or cryptogenic stroke. In this case report, a female patient with Anderson–Fabry disease and left ventricular hypertrophy is described. In addition to highlighting the importance of cardiac disease in female heterozygotes, the case also illustrates the importance of taking a careful family history in establishing the diagnosis of Anderson–Fabry disease within an affected family.

■ *Heart Metab.* 2006;33:25–29.

Keywords: Anderson–Fabry disease, left ventricular hypertrophy, women

Case report

Mrs X presented for the first time in 1995 when she was assessed by her general practitioner for hormone replacement therapy. She complained of no cardiac symptoms and was normotensive, but a routine electrocardiogram was abnormal, with evidence of left ventricular hypertrophy. Subsequent echocardiography confirmed the presence of concentric left ventricular hypertrophy. No further evaluation or management was suggested.

In 2004, Mrs X started to experience chest pain and dyspnea when walking up stairs and inclines. On systematic questioning she complained of tinnitus. A careful family pedigree was taken (*Figure 1*). Her sister in Australia had been diagnosed with hypertrophic cardiomyopathy and had a son in his mid-30s with end-stage renal disease. Mrs X's mother, sister, and daughter had a history of deafness. In 2003, her brother had presented at the age of 70 years with

presyncopal ventricular tachycardia associated with a small increase in serum, troponin. Coronary angiography demonstrated no flow-limiting stenosis and he received an internal cardioverter defibrillator. He subsequently presented with an episode of transient right hemiplegia and syncope with transient amnesia.

Clinical examination of Mrs X revealed a regular pulse of 60 beats/min and a blood pressure of 130/80 mm Hg. No other abnormalities were found. The electrocardiogram (*Figure 2*) demonstrated left atrial enlargement and left ventricular hypertrophy, with repolarization abnormalities in leads I, II, aVL, and V4–6. Echocardiography demonstrated concentric left ventricular hypertrophy, with a maximum left ventricular wall thickness of 18 mm and mild right ventricular hypertrophy (*Figure 3*). Conventional measures of systolic function were normal, but the Doppler study suggested the presence of increased left ventricular filling pressure. There was

Case report

Perry Elliott

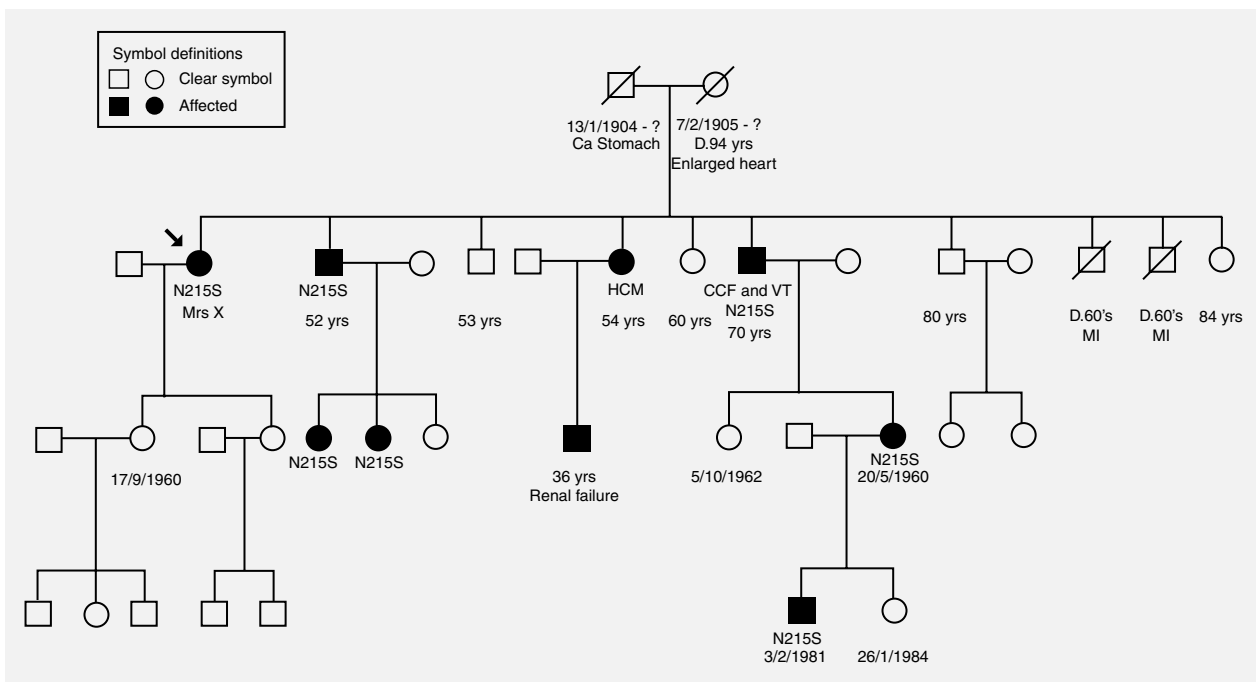


Figure 1. Family pedigree. At the time of presentation, there was a family history of cardiomyopathy and renal disease. The results of genotyping are shown (carriers of N215S mutation). Open symbols, clear; solid symbols, affected.

incomplete systolic anterior motion of the mitral valve, without evidence of left ventricular outflow tract obstruction and obliteration of the mid-ventricular cavity in systole. The left atrium was mildly dilated, at 45 mm.

In view of the concentric distribution of hypertrophy and the family history of deafness, cardiomyopathy,

and renal disease, plasma α -galactosidase A was measured and found to be within the diagnostic range for Anderson–Fabry disease (2.14 nmol/h per ml; normal range 4–21.9 nmol/h per ml). Subsequent genetic analysis demonstrated that Mrs X was heterozygous for an AAT→AGT mutation at codon 215 of exon 5, resulting in an Asn²¹⁵Ser (N215S) substitution.

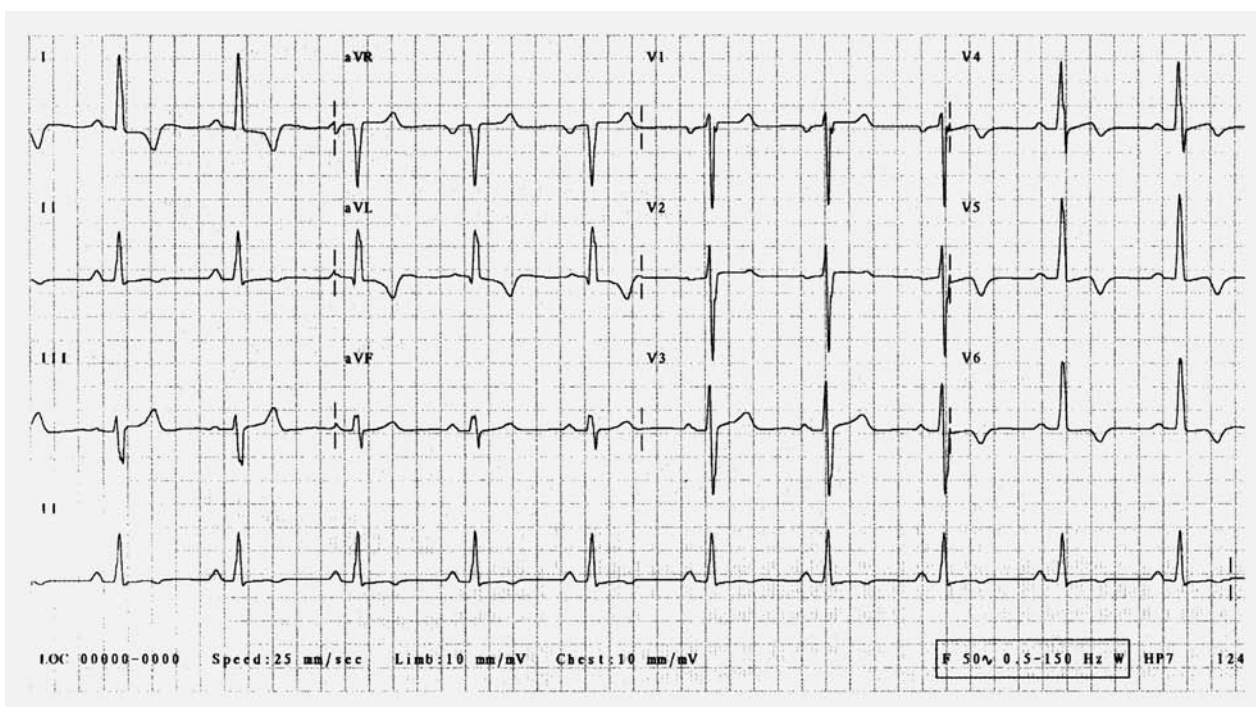


Figure 2. Standard 12-lead electrocardiogram demonstrating left ventricular hypertrophy and left atrial enlargement.

Case report

Anderson–Fabry disease and unexplained LVH

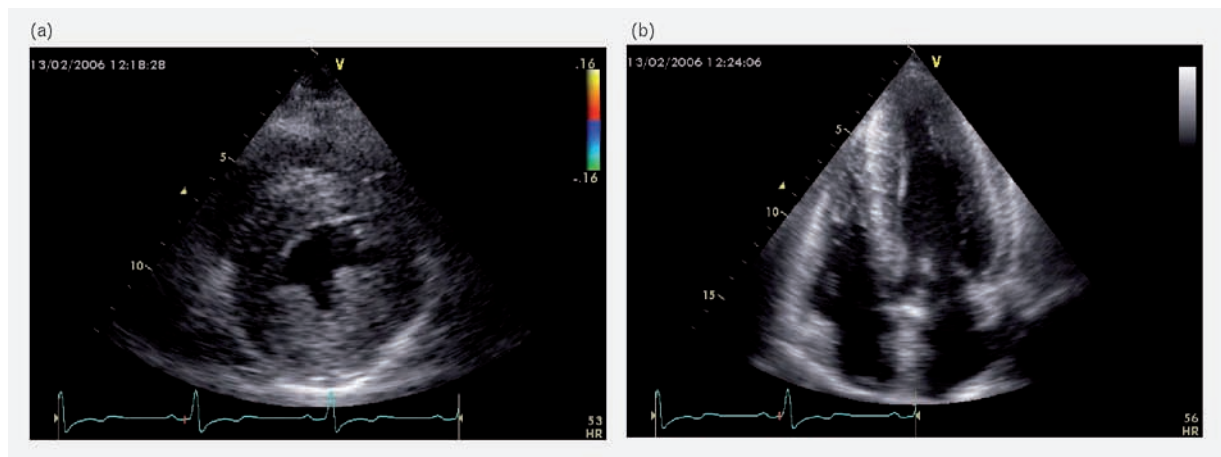


Figure 3. (a) Two-dimensional echocardiogram showing short-axis view of the left ventricle at mitral valve level. There is concentric left ventricular hypertrophy, with enlargement of the papillary muscles. (b) Two-dimensional echocardiogram showing apical four-chamber view. There is hypertrophy of both the left and right ventricles.

The same mutation was identified in other affected family members (Figure 1).

Because of her chest pains, Mrs X was advised to undergo coronary angiography, but she declined to do so. Further evaluation demonstrated a glomerular filtration rate of 81 ml/min and hearing loss to all frequencies on the left. In view of her mild renal impairment, tinnitus, and significant cardiac disease, she was commenced on treatment with agalsidase alfa (Replagal) in 2005.

Discussion

Anderson–Fabry disease is caused by mutations in the gene encoding the lysosomal enzyme α -galactosidase A [1,2]. This results in reduced or absent α -galactosidase A activity and intra-lysosomal accumulation of neutral glycosphingolipids, mainly globotriaosylceramide (Gb3), in various organ systems. Anderson–Fabry disease is characterized by progressive clinical manifestations and premature death from renal disease, stroke, and cardiac disease [1–4].

Historically, Anderson–Fabry disease has been believed to be a rare disease, but a recent study using an α -galactosidase A assay on blood spots from 37 104 consecutive Italian male neonates, has demonstrated a prevalence of 0.03% and an incidence of α -galactosidase A deficiency of 1 in 3100, with an 11 : 1 ratio of patients with the later-onset as opposed to the classic phenotype [5]. These data are in accordance with findings of studies that have reported a prevalence of 0.2–1.2% in patients with end-stage renal disease on hemodialysis and 4.9% in men with cryptogenic stroke [6,7]. The prevalence of Anderson–Fabry disease in men with unexplained left ventricular hypertrophy is reported to be at least 3–4% and may be greater in studies that have used endomyocardial biopsy as a screening tool [8–10].

Although many symptoms occur in childhood, a correct diagnosis can be delayed by as much as 14 years in males and 16 years in females (Fabry Outcome Survey) [2]. In males, symptoms often start in the first decade of life with acroparesthesias and pain, febrile crises, hypohidrosis, heat intolerance, gastrointestinal disturbance, and the development of cutaneous angiokeratomata. From the second decade onwards, patients develop proteinuria and neurological manifestations, including vestibular and hearing disturbance, and autonomic dysfunction. Cardiac involvement is present early in life, but is not detected clinically until the third or fourth decade [1–4]. The main causes of death are end-stage renal disease, heart failure, arrhythmia, and stroke.

The “cardiac variant”

A number of reports have suggested that some patients with residual α -galactosidase activity (approximately 1–5% of normal values) present in middle age with left ventricular hypertrophy and conduction disease, in the absence of other classical disease manifestations [1,8,9]. Patients with this so-called “cardiac variant” may have proteinuria, but are said not to develop end-stage renal disease. Contemporary studies have suggested that the term “cardiac variant of Anderson–Fabry disease” is a misnomer, as rigorous clinical characterization usually reveals disease in other organs. Nevertheless, clinical presentation in patients with residual activity may be dominated by cardiovascular signs and symptoms.

Genetics of Anderson–Fabry disease

Anderson–Fabry disease results from mutations in the α -galactosidase gene, located on the long arm of the X chromosome (Xq22.1) [1,11–14]. The gene consists of seven exons that encode a 101 kDa homodimeric

Case report

Perry Elliott

glycoprotein that exists in a number of natural forms defined by different sialic acid residues on carbohydrate chains. More than 200 mutations have been described in all seven exons, the majority of which are missense point mutations [1,12–14].

Reduced enzyme activity occurs by several mechanisms, including abnormal/unstable protein folding, perturbation of the active binding site, and defects in enzyme tracking to the lysosome [1,14,15]. More than 90% of the described mutations are associated with the classical phenotype [1] and fewer than 20 are associated with the so-called cardiac phenotype. The N215S mutation that was responsible for disease in Mrs X is a missense mutation that results in abnormal glycosylation [14,15]. In the first descriptions of this mutation, the clinical phenotype was typically mild. As can be seen in this case study, however, expression varies enormously between individuals.

Disease in females

Disease manifestations were believed to be rare or mild in female carriers, but data from the Fabry Outcome Survey and other sources show that most affected women have signs or symptoms of disease, with a similar prevalence of fatigue and neurological and gastrointestinal symptoms as in men [2–4]. Despite a lower prevalence of left ventricular hypertrophy, females have a similar prevalence of cardiac symptoms such as angina, dyspnea, and palpitations. The frequency of symptoms and signs related to Anderson–Fabry disease increases with age in both men and women, and it has been suggested that females with Anderson–Fabry disease have a 15-year reduction in their lifespan when compared with the general population [3].

The findings of a twin study have suggested that the mechanism of non random X inactivation (lyonization) may result in disease expression in females [16]. This hypothesis was further strengthened by a recent study that demonstrated a higher Mainz Severity Score (a validated score for disease severity) in females with non random X inactivation demonstrated in peripheral blood, compared with those without [11].

Enzyme replacement therapy

There are two recombinant enzyme preparations approved for the treatment of Anderson–Fabry disease in Europe: agalsidase-alpha (produced in human fibroblasts) and agalsidase-beta (produced in a Chinese hamster ovarian cell line). Enzyme uptake is mediated by mannose-6-phosphate, mannose, and asialoglycoprotein receptors. Several studies have shown that these preparations can improve neurological and renal function, in addition to quality of life [17–21]. A phase 3 trial using agalsidase-alpha has

demonstrated an improvement in duration of the QRS complex [17] and Gb3 clearance from vascular endothelial cells [18]. Case reports and observational clinical studies have shown improvements in left ventricular size and function with both treatments [22–24].

As Anderson–Fabry disease is an X-linked disease, sex has a major influence on cardiac involvement. Although definitive proof of the long-term beneficial effects of enzyme replacement therapy in men and women with disease are awaited, Mrs X was considered to have sufficient organ involvement to warrant treatment.

Conclusions

Cardiovascular disease accounts for much of the morbidity associated with Anderson–Fabry disease in men and women. This case illustrates the importance of Anderson–Fabry disease as a cause for otherwise unexplained cardiac hypertrophy in both men and women. It also shows how careful systematic questioning and a detailed family pedigree can provide clues to the diagnosis.

Conflict of interest

Dr Elliott acts as a consultant for Genzyme Inc. and Shire Human Genetics Therapies. He is a member of the International Board of The Fabry Outcome Survey (FOS). ■

REFERENCES

1. Desnick RJ, Ioannou YA, Eng CM. α -Galactosidase A deficiency: Fabry disease. In: *The Metabolic and Molecular Bases of Inherited Disease*, 8th edn. Edited by Scriver CR, Beaudet AL, Sly WS, Valle D. New York: McGraw-Hill; 2001. pp. 3733–3774.
2. Mehta A, Ricci R, Widmer U, et al. Fabry disease defined: baseline clinical manifestations of 366 patients in the Fabry Outcome Survey. *Eur J Clin Invest*. 2004;34:236–242.
3. MacDermot KD, Holmes A, Miners AH. Anderson–Fabry disease Clinical manifestations and impact of disease in a cohort of 60 obligate carrier females. *J Med Genet*. 2001;38:769–775.
4. MacDermot KD, Holmes A, Miners AH. Anderson–Fabry disease Clinical manifestations and impact of disease in a cohort of 98 hemizygous males. *J Med Genet*. 2001;38:750–760.
5. Spada M, Pagliardini S, Yasuda M, et al. High incidence of later-onset Fabry disease revealed by newborn screening. *Am J Hum Genet*. 2006;79:31–40.
6. Kotanko P, Kramar R, Devrnja D, et al. Results of a nationwide screening for Anderson–Fabry disease among dialysis patients. *J Am Soc Nephrol*. 2004;15:1323–1329.
7. Rolfs A, Böttcher T, Zschiesche M, et al. Prevalence of Fabry disease in patients with cryptogenic stroke: a prospective study. *Lancet*. 2005;366:1794–1796.
8. Nakao S, Takenaka T, Maeda M, et al. An atypical variant of Fabry's disease in men with left ventricular hypertrophy. *N Engl J Med*. 1995;333:288–293.

Case report

Anderson–Fabry disease and unexplained LVH

- Sachdev B, Takenaka T, Teraguchi H, et al. Prevalence of Anderson–Fabry disease in male patients with late onset hypertrophic cardiomyopathy. *Circulation*. 2002;105:1407–1411.
- Chimenti C, Pieroni M, Morgante E, et al. Prevalence of Fabry disease in female patients with late-onset hypertrophic cardiomyopathy. *Circulation*. 2004;110:1047–1053.
- Dobrovolny R, Dvorakova L, Ledvinova J, et al. Relationship between X-inactivation and clinical involvement in Fabry heterozygotes. Eleven novel mutations in the α -galactosidase A gene in the Czech and Slovak population. *J Mol Med*. 2005;3:647–654.
- Garman SC, Garboczi DN. Structural basis of Fabry disease. *Mol Genet Metab*. 2002;77:3–11.
- Pastores GM, Lien Y. Biochemical and molecular basis of Fabry disease. *J Am Soc Nephrol*. 2002;13:S130–S133.
- Eng CM, Resnick-Silverman LA, Niehaus DJ, Astrin KH, Desnick RJ. Nature and frequency of mutations in the alpha-galactosidase A gene that cause Fabry disease. *Am J Hum Genet*. 1993;53:1186–1197.
- Desnick RJ, Schuchman EH. Enzyme therapy and enhancement therapies: lessons from lysosomal disorders. *Nature*. 2002;3:954–966.
- Redonnet-Vernhet I, Ploos van Amstel JK, Jansen RPM, et al. Uneven X inactivation in a female monozygotic twin pair with Fabry disease and discordant expression of a novel mutation in the alpha-galactosidase A gene. *J Med Genet*. 1996;33:682–688.
- Schiffmann R, Kopp JB, Austin HA 3rd, et al. Enzyme replacement therapy in Fabry disease: a randomized controlled trial. *JAMA*. 2001;285:2743–2749.
- Eng CM, Guffon N, Wilcox WR, et al., for the International Collaborative Fabry Disease Study Group. Safety and efficacy of recombinant human alpha-galactosidase A – replacement therapy in Fabry’s disease. *N Engl J Med*. 2001;345:9–16.
- Beck M, Ricci R, Widmer U, et al. Fabry disease: overall effects of agalsidase alfa treatment. *Eur J Clin Invest*. 2004;34:838–844.
- Schiffmann R, Floeter MK, Dambrosia JM, et al. Enzyme replacement therapy improves peripheral nerve and sweat function in Fabry disease. *Muscle Nerve*. 2003;28:703–710.
- Moore DF, Altarescu G, Ling GS, et al. Elevated cerebral blood flow velocities in Fabry disease with reversal after enzyme replacement. *Stroke*. 2002;33:525–531.
- Weidemann F, Breunig F, Beer M, et al. Improvement of cardiac function during enzyme replacement therapy in patients with Fabry disease: a prospective strain rate imaging study. *Circulation*. 2003;108:1299–1301.
- Spinelli L, Pisani A, Sabbatini M, et al. Enzyme replacement therapy with agalsidase beta improves cardiac involvement in Fabry’s disease. *Clin Genet*. 2004;66:158–165.
- Komamura K, Higashi M, Yamada N. Improvement of cardiac hypertrophy and ventricular function in a man with Fabry disease by treatment with recombinant alpha-galactosidase A. *Heart*. 2004;90:617.