

Breathlessness and damaging lifestyle in a patient with pre-diabetes: will trimetazidine help?

AQ2

Graham Jackson

Department of Cardiology, Guy's & St Thomas' NHS Foundation Trust, London, UK

Correspondence: Graham Jackson, Department of Cardiology, Guy's & St Thomas' NHS Foundation Trust, Road?, London SE1 7EH, UK.
E-mail: gjcardiol@talk21.com

AQ3

Abstract

A case of ischemic left ventricular dysfunction worsened by excessive alcohol consumption is reported. In addition to improving symptoms of breathlessness, the addition of trimetazidine to conventional evidence-based medicine may improve this patient's prognosis, secondary to its cardioprotective actions. Lifestyle advice complements any medical therapeutic strategy and should be routinely incorporated into the management of a patient.

■ *Heart Metab.* 2007;35:1–2.

Keywords: Alcohol excess, pre-diabetes, left ventricular dysfunction, lifestyle, trimetazidine

AQ4

Case report

A 60-year-old man with pre-diabetes (glucose 6.4 mmol/L) had been a regular attender at the cardiac clinic. In the past he had undergone coronary artery bypass surgery after a large inferior infarct (*Figure 1*). He had been treated for ventricular tachycardia with an implantable defibrillator and amiodarone and, because of his reduced ejection fraction (30%), a resynchronization pacing system. He again presented at the clinic, on this occasion complaining of breathlessness on effort; he did not experience chest pain. In addition to amiodarone he was taking bisoprolol 2.5 mg, frusemide 40 mg, perindopril 8 mg, spironolactone 25 mg daily, atorvastatin 20 mg, and aspirin 75 mg daily.

Unfortunately, the patient's lifestyle was not helping his management. He denied drinking an excess of alcohol, but accepted that he drank daily; however, his γ -glutamyl transpeptidase enzyme concentration was 1352 units (normal value <72 units), indicating a considerable ingestion of alcohol. He was overweight and smoked an average of 10 cigarettes a day.

The patient's belief that he could be cured by further cardiac surgery had not been supported by a recent coronary angiogram, which had identified a good left internal mammary artery graft to a stenosed left anterior descending artery, no significant circumflex disease, and an occluded right coronary artery subtending the inferior infarct. Discussions with the cardiac surgical team and interventional cardiologists resulted in a decision to continue medical treatment because no target lesions were available for intervention. In addition, a perfusion scan confirmed the major problem to be irreversible left ventricular dysfunction, with no areas of reversible ischemia.

The patient's treatment was reviewed and seen to be evidence-based. His blood pressure was 115/72 mmHg and examination revealed no evidence of volume overload, but bronchospasm caused by smoking was noted (it was not felt necessary to stop the β -blocker). The only therapeutic option other than radically altering his lifestyle was to introduce trimetazidine 20 mg three times daily.

After 2 months of treatment, the patient showed signs of symptomatic improvement, with less breathlessness.

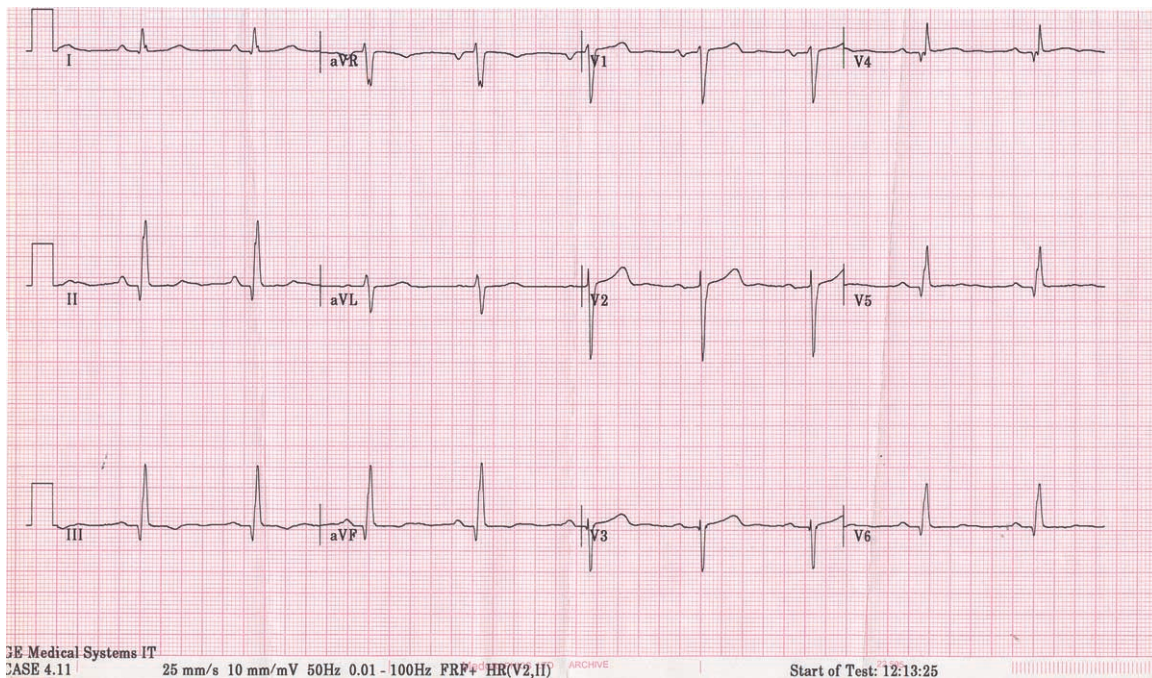


Figure 1. 12-Lead electrocardiogram demonstrating sinus rhythm and evidence of old inferior infarction.

An echocardiogram gave unchanged findings with regard to ejection fraction, but there may be improvement over time. He had not modified his lifestyle, in spite of a concerted effort from his family doctor and the suggestion that he might join a cardiac rehabilitation program, which he declined to do.

Comment

Some patients are their own worst enemies. This man's left ventricular dysfunction was secondary to his documented coronary disease, with excess alcohol consumption further compromising his cardiac output. In spite of his lifestyle, he now remains a regular attendee seeking help and is compliant with his medication. He has been offered help from several medical agencies, but continues to fail to change his ways. The difficulty in managing cases of this nature is both frustrating and time-consuming. However, all individuals merit the same medical opportunities, whether they are 'good' or 'bad' patients.

The encouraging evidence for improvement in left ventricular function with trimetazidine [1,2] was explained in detail to the patient and he agreed to

pursue this medical approach. Of relevance to him is the evidence of improvement in ejection fraction in the presence of coronary artery disease, suggesting a benefit at the cellular level. In addition to improving glucose metabolism, trimetazidine may diminish mitochondrial uncoupling, enhance the efficiency of production of ATP, and reduce apoptosis [1]. The patient reported here could benefit symptomatically and, in theory, prognostically from the addition of trimetazidine to his treatment [2,3]. It will also be interesting to see if his vulnerability to ventricular arrhythmias decreases as the adverse effects of free fatty acids on the myocardium are reduced. ■

REFERENCES

1. Essop MF, Opie LH. Metabolic therapy for heart failure. *Eur Heart J.* 2004;25:1765–1768.
2. Jackson G. Metabolic approach to heart failure – evidence that trimetazidine improves symptoms, left ventricular function and possibly prognosis. *Int J Clin Pract.* 2006;60:891–892.
3. Fragasso G, Perseghin G, DeCobelli F, et al. Effects of metabolic modulation by trimetazidine on left ventricular function and phosphocreatine/adenosine triphosphate ratio in patients with heart failure. *Eur Heart J.* 2006;27:942–948.