

# Metabolic imaging: the role of imaging in risk evaluation of ischemic heart disease

Mark T. Harbinson

Division of Medicine and Therapeutics, Queen's University Belfast, Department of Cardiology, Belfast City Hospital, Belfast, N. Ireland

Correspondence: Dr Mark Harbinson, Division of Medicine and Therapeutics, Whitla Building, Queen's University Belfast, 97 Lisburn Road, Belfast BT7 9BL, N. Ireland.  
Tel: +02890 975770; e-mail: m.harbinson@qub.ac.uk

### Abstract

In ischemic heart disease (IHD), understanding the pathophysiology, and relating this to prognosis, are of prime importance. Many important physiological parameters have been shown to be closely related to patient outcome in IHD. Myocardial perfusion, myocardial cell viability, left ventricular function, response of dysfunctional myocardium to revascularization, and cardiac sympathetic innervation represent important metabolic targets in such patients. Nuclear imaging techniques utilizing radioisotopes designed to probe these processes have advanced our understanding of the underlying pathophysiology of IHD, and have provided robust markers of risk and prognosis suitable for use in routine clinical practice.

■ *Heart Metab.* 2007;36:15–18.

**Keywords:** Ischemic heart disease, metabolic tracers, myocardial perfusion imaging, nuclear cardiology, prognosis

### Introduction

This issue of *Heart and Metabolism* addresses the important subject of prognosis in ischemic heart disease (IHD). In this review, the application of metabolic imaging techniques to this problem is discussed. Clearly, it is impossible to make a comprehensive survey of all the possible techniques available, and here the focus will be on the use of radionuclide tracers that help to define the underlying pathophysiological and metabolic processes that have an impact on patient prognosis. Other imaging techniques that describe metabolic processes such as magnetic resonance spectroscopy [1] are not included because of space constraints.

### Imaging myocardial ischemia

From a clinical perspective, prognosis in IHD is dominated by left ventricular systolic function, the extent of myocardial ischemia (which is related to the extent of coronary artery disease), and the risk of fatal ventricular arrhythmias; the last is closely linked to the first two. It is not surprising, therefore, that myocardial perfusion abnormalities, which represent ischemia, are very strong prognostic markers in IHD. Radionuclide tracers such as thallium-201 ( $^{201}\text{Tl}$ ) and technetium-99m ( $^{99\text{m}}\text{Tc}$ ) have been used for many years to demonstrate myocardial ischemia in man. Both tracers are extracted from the blood into the myocardium according to coronary blood flow, and

# Metabolic imaging

Mark T. Harbinson

their distribution is imaged using a gamma camera. The amount of tracer uptake in the heart is determined after a resting injection (representing resting perfusion) and then after either exercise or pharmacological stress (representing stress perfusion). A defect in stress perfusion that normalizes on the resting study represents myocardial ischemia. There have been several studies over many years showing this to be a very powerful prognostic discriminator, both in large populations and in defined subgroups such as men, women, patients with diabetes, and patients who have previously undergone revascularization [2–4]. The extent of ischemia in terms of the amount of left ventricle involved, and the depth of ischemia in terms of the severity of the reduction in perfusion, are, independently and in combination, powerful predictors of death and coronary events, including myocardial infarction [5]. A normal myocardial perfusion study predicts a very low likelihood of myocardial infarction or death (usually less than 1% per year), but an abnormal study predicts major events in an incremental fashion correlated with the degree of imaging abnormality [5, 6].

## Imaging left ventricular systolic function

Although, strictly speaking, it is generally not interrogated in a metabolic sense by imaging techniques, left ventricular systolic function remains one of the most important determinants of prognosis in IHD [7]. Numerous studies have shown a clear link between left ventricular function and prognosis, particularly cardiac death, heart failure, and arrhythmias. For example, gated myocardial perfusion imaging with technetium agents has shown that, in IHD, prognosis in terms of cardiac death is predicted by left ventricular ejection fraction and end-systolic volume [8]. Other imaging techniques, including echocardiography, have become routine tools for assessing systolic function. Recently, cardiac magnetic resonance imaging has gained prominence because of its excellent reproducibility and accuracy in a variety of clinical settings.

## Imaging myocardial viability and metabolism

In addition to perfusion and functional information, radionuclides provide information about the metabolic status of the myocardium. The resting uptake of the tracers discussed above depends, not only on the state of myocardial perfusion, but on the active metabolic processes of the myocardium. Tracer is taken up only into myocardium that is alive (“viable” or metabolically active). This is important in IHD, because the amount of viable myocardium is related to patient

prognosis in two ways. First, it has been shown that patients with large myocardial infarctions and little viable remaining tissue have an adverse prognosis [9]. Secondly, there is a strong suggestion from the findings of many relatively small studies that patients with chronic ischemic left ventricular dysfunction experience a prognostic benefit when revascularization is undertaken in the setting of large amounts of viable myocardium; conversely, in the absence of viable myocardium, revascularization seems to have little benefit [10].

In general, radionuclides that reflect metabolic activity in the heart are viability tracers. Thallium-201 is an analog of potassium and exchanges across myocardial cell membranes, and thus reflects myocardial cell membrane integrity [11]. Technetium-99m is taken up into myocytes into the cytosol or mitochondria, and resting uptake therefore reflects myocardial cell membrane integrity and adequate mitochondrial function [12] (Figure 1). The positron-emitting tracer,

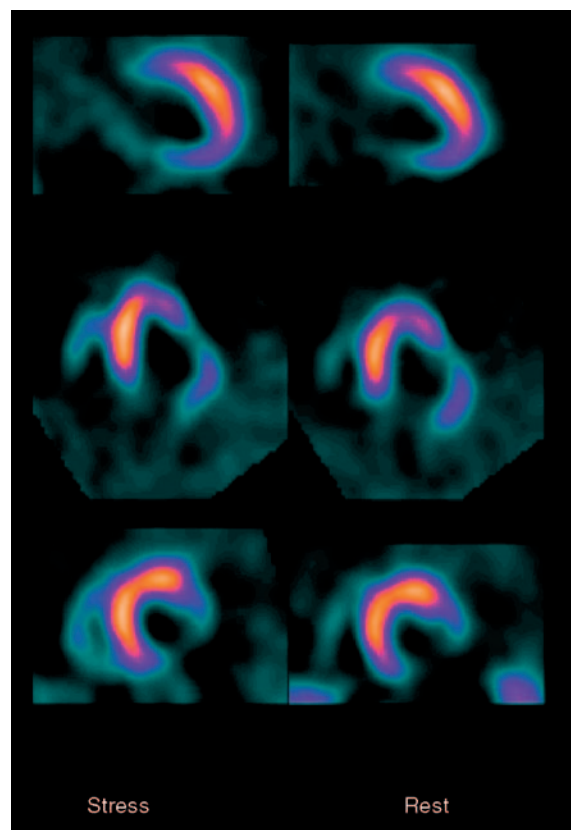


Figure 1. Stress (left) and rest (right)  $^{99m}\text{Tc}$  myocardial perfusion tomograms in selected vertical long axis (top), horizontal long axis (middle), and short axis (bottom) orientation. The images show absence of tracer uptake in the basal and mid inferior and lateral territories, with relatively normal uptake elsewhere. The lack of tracer uptake in the inferolateral territory is compatible with transmural myocardial infarction in this territory, and suggests that there is no viable myocardium in the territory. The absence of difference between the images implies that there is little residual ischemia.

# Metabolic imaging

Risk stratification by imaging in coronary disease

18-fluorodeoxyglucose (FDG), is transported into the myocardium in the same way as glucose, and is then phosphorylated to FDG-6-PO<sub>4</sub>, which remains fixed within the cell [13]. Cardiac uptake of FDG therefore reflects the extent of metabolically active myocardium that is capable of utilizing glucose as a substrate. Other tracers similarly evaluated in man include [<sup>11</sup>C]acetate, which reflects the extent of oxidative phosphorylation within myocytes and has also been shown to predict functional recovery after revascularization [14]. Rubidium-82, a positron-emitting tracer frequently used to assess myocardial perfusion, has in addition been shown to predict outcome on the basis of the amount of viable myocardium it demonstrates [9]. Therefore, radiotracers which show that various aspects of myocardial metabolism are still intact can identify viable myocardium and, when associated with the presence of ischemic dysfunction, can select those myocardial segments which – and thus those patients who – may gain a prognostic advantage from revascularization. Demonstrating the metabolic signature of myocardial hibernation therefore carries prognostic and therapeutic information.

## Imaging cardiac neuronal function

Another aspect of metabolism in which there has been renewed interest recently is cardiac sympathetic innervation. Sympathetic nervous function is often abnormal in patients with left ventricular dysfunction and heart failure, and abnormalities in this parameter have prognostic importance. [<sup>123</sup>I]Metaiodobenzylguanidine (MIBG) is a radioactively labeled norepinephrine (noradrenaline) analog that is taken up by presynaptic nerve terminals and is handled in the same way as norepinephrine. Abnormalities of the cardiac sympathetic nervous system can therefore be evaluated from the scintigraphic pattern of uptake of [<sup>123</sup>I]MIBG. In heart failure, uptake of MIBG by cardiac sympathetic nerves is reduced because of high turnover as a result of increased sympathetic tone. In addition, there may be damage to the sympathetic coverage of the heart in parallel with myocardial damage in patients with IHD. Uptake of [<sup>123</sup>I]MIBG by the heart is compared with that in a non heart area, usually the mediastinum, to give a heart–mediastinal ratio. Reduced heart–mediastinal ratio indicates poor sympathetic coverage and is an adverse prognostic factor in patients with heart failure [15–17]. There is current interest in the evaluation of this metabolic marker in assessing prognosis related to the likelihood of ventricular arrhythmias and the selection of patients for implanted defibrillator therapy.

## Imaging other underlying metabolic processes

Gamma tracers for other metabolic processes in man (such as the tracer, annexin V, which images apoptotic cells, and [<sup>123</sup>I]β-methyliodophenyl pentadecanoic acid, which assesses fatty acid metabolism) have been assessed in recent years [18,19]. Many positron tracers probing a variety of underlying cardiac metabolic processes have been evaluated in small studies, and many more are currently under investigation [20]. These are all promising, but there are as yet no compelling long-term data in man to establish their place as established imaging markers of prognosis.

## Conclusion

There are currently commercially available, in daily clinical practice, nuclear tracers that can accurately reflect several underlying cardiac metabolic processes, including myocardial perfusion and myocardial cell integrity, the imaging of which is closely linked to prognosis in large series of patients.

## Summary

In this article, the role of imaging techniques for assessing various pathophysiological and metabolic aspects of cardiac function in ischemic heart disease is discussed. Important metabolic processes that are closely linked with patient prognosis in clinical trials may be interrogated using nuclear radioisotopes designed for specific cardiac targets. The critical predictors of patient prognosis in IHD, including myocardial perfusion, myocardial cell viability, and left ventricular function, can be assessed using gamma-emitting radiotracers such as thallium-201 or technetium-99m. Other metabolic targets linked to prognosis, such as cardiac sympathetic function (assessed with [<sup>123</sup>I]MIBG) are coming to the point of more routine clinical use, and various other tracers for different processes are currently under investigation. The role of metabolic imaging in cardiology is set to step closer to clinical application in the next few years. ■

## REFERENCES

1. Bottomley PA. MR spectroscopy of the human heart: the status and the challenges. *Radiology*. 1994;191:593–612.
2. Marwick TH, Shaw LJ, Lauer MS, et al. The noninvasive prediction of cardiac mortality in men and women with known or suspected coronary artery disease. Economics of Noninvasive Diagnosis (END) study group. *Am J Med*. 1999;106:172–178.

---

# Metabolic imaging

Mark T. Harbinson

---

- Zellweger MJ, Lewin HC, Lai S, et al. When to stress patients after coronary artery bypass surgery? Risk stratification in patients early and late post-CABG using stress myocardial perfusion SPECT: implications of appropriate clinical strategies. *J Am Coll Cardiol*. 2001;37:144–152.
- Kang X, Berman DS, Lewin HC, et al. Incremental prognostic value of myocardial perfusion single photon emission computed tomography in patients with diabetes mellitus. *Am Heart J*. 1999;138:1025–1032.
- Hachamovitch R, Berman DS, Kiat H, et al. Exercise myocardial perfusion SPECT in patients with known coronary artery disease: incremental prognostic value and use in risk stratification. *Circulation*. 1996;93:905–914.
- Brown KA. Prognostic value of thallium myocardial perfusion imaging: a diagnostic tool comes of age. *Circulation*. 1991;83:363–381.
- White HD, Norris RM, Brown MA, Brandt PW, Whitlock RM, Wild CJ. Left ventricular end-systolic volume as the major determinant of survival after recovery from myocardial infarction. *Circulation*. 1987;76:44–51.
- Sharir T, Germano G, Kavanagh PB, et al. Incremental prognostic value of post-stress left ventricular ejection fraction and volume by gated myocardial perfusion single photon emission computed tomography. *Circulation*. 1999;100:1035–1042.
- Yoshida K, Gould KL. Quantitative relation of myocardial infarct size and myocardial viability by positron emission tomography to left ventricular ejection fraction and 3-year mortality with and without revascularisation. *J Am Coll Cardiol*. 1993;22:984–997.
- Bax JJ, van der Wall EE, Harbinson M. Radionuclide techniques for the assessment of myocardial viability and hibernation. *Heart*. 2004;90:v26–v33.
- Dilsizian V, Borrow RO. Current diagnostic techniques for assessing myocardial viability in patients with hibernating and stunned myocardium. *Circulation*. 1993;87:1–20.
- Borrow RO, Dilsizian V. Thallium-201 and technetium-99m sestamibi for assessing viable myocardium. *J Nuc Med*. 1992;33:815–818.
- Bax JJ, Patton JA, Poldermans D, Elhendy A, Sandler MP. 18-Fluorodeoxyglucose imaging with PET and SPECT: cardiac applications. *Semin Nucl Med*. 2000;30:281–298.
- Gropler RJ, Geltman EM, Sampathkumaran K, et al. Comparison of carbon-11 acetate with fluorine-18-fluorodeoxyglucose for delineating viable myocardium by positron emission tomography. *J Am Coll Cardiol*. 1993;22:1587–1597.
- Merlet P, Valette H, Dubois-Rande JL, et al. Prognostic value of cardiac metaiodobenzylguanidine imaging in patients with heart failure. *J Nucl Med*. 1992;33:471–477.
- Wakabayashi T, Nakata T, Hashimoto A, et al. Assessment of underlying etiology and cardiac sympathetic innervation to identify patients at high risk of cardiac death. *J Nucl Med*. 2001;42:1757–1767.
- Anastasiou-Nana MI, Terrovitis JV, Athanasoulis T, et al. Prognostic value of iodine-123-metaiodobenzylguanidine myocardial uptake and heart rate variability in chronic congestive heart failure secondary to ischemic or idiopathic dilated cardiomyopathy. *Am J Cardiol*. 2005;96:427–431.
- Hofstra L, Liem IH, Dumont E, et al. Visualization of cell death in vivo in patients with acute myocardial infarction. *Lancet*. 2000;356:209–212.
- Kawai Y, Tsukamoto E, Nozaki Y, Morita K, Sakurai M, Tamaki N. Significance of reduced uptake of iodinated fatty acid analogue for the evaluation of patients with acute chest pain. *J Am Coll Cardiol*. 2001;38:1888–1894.
- Russell RR, Zaret BL. Nuclear cardiology: present and future. *Curr Probl Cardiol*. 2006;31:557–629.