

Clinical manifestations of diabetic cardiomyopathy

Sihem Boudina

Division of Endocrinology Metabolism and Diabetes, Program in Molecular Medicine,
University of Utah School of Medicine, Salt Lake City, Utah, USA

Correspondence: Dr Sihem Boudina, HMBG, 15N 2030E bldg 533 rm 3145, Salt Lake City, UT 84112, USA.
Tel: +1 (801) 585 6833; e-mail: Sihem.boudina@hmbg.utah.edu

Conflict of interest: None.

Abstract

Patients with diabetes have an increased incidence of heart failure, even after analyses have controlled for coronary artery disease and hypertension. Thus, as diabetic cardiomyopathy (DCM) has become a well recognized entity among clinicians, a better understanding of its development is necessary for the early diagnosis and the future treatment of diabetes-associated cardiovascular disease. In this article, the latest clinical research on the diagnosis and manifestations of DCM will be outlined. The discussion will be focused on the structural, functional, and metabolic changes that occur in the diabetic myocardium and how these changes contribute to the development of DCM in humans.

■ *Heart Metab.* 2009;45:10–14.

Keywords: Diabetic cardiomyopathy, diastolic dysfunction, fibrosis, mitochondrial dysfunction, substrate utilization

Introduction

About three decades ago, Rubler et al [1] first introduced the concept of “diabetic cardiomyopathy” (DCM), which has since been extensively used by epidemiologists and clinicians. DCM is defined as a disease that directly affects the structure and the function of the myocardium, in the absence of other confounding factors such as coronary artery disease (CAD) or hypertension. These early alterations that progress with other diabetes-associated complications lead to the development of more clinically recognized conditions such as left ventricular hypertrophy and heart failure [2].

Structural changes

Left ventricular hypertrophy

Increased left ventricular mass is an independent marker of cardiovascular risk that often occurs inde-

pendently of arterial blood pressure in type 2 diabetes. Thus diabetes is an independent contributor to left ventricular hypertrophy (LVH) and myocardial stiffness* [3]. The Framingham study investigators used echocardiography and reported a significant increase in left ventricular wall thickness in women with diabetes [4]. This was further confirmed in a follow-up study on the Framingham offspring, which also showed that women with diabetes experienced a steeper increase in left ventricular mass with advancing age compared with men and those without diabetes [5]. In contrast, the Strong Heart Study, conducted in a population of American Indians, found that both men and women with diabetes had greater left ventricular mass and wall thickness [6]. Furthermore, in a multi-ethnic population, the likelihood of having left ventricular mass above the 75th percentile of the distribution was 1.5-fold greater in patients with type 2 diabetes, independently of various covariates, including hypertension [7]. In this same population, it was shown that increased left ventricular mass can be

Main clinical article

Clinical manifestations of diabetic cardiomyopathy

seen only in patients with diabetes, as compared with patients with impaired or normal fasting glucose concentrations [8], suggesting that alterations in the geometry of the heart in diabetic individuals are not an early defect but, rather, a consequence of changes associated with diabetes such as hyperglycemia or obesity. Indeed, Eguchi et al [7] found a significant interaction between diabetes and central obesity and the risk for LVH. Although associations between type 2 diabetes and LVH have been well studied, the influence of type 1 diabetes on left ventricular mass is not well characterized. For example, increased left ventricular wall stiffness was detected in women with type 1 diabetes [9], but 50% of these patients had microvascular complications and some exhibited abnormalities in autonomic function tests; furthermore, in a small cohort of patients with long-standing type 1 diabetes, improved glycemic control significantly reduced septal thickness and left ventricular mass when compared with those in patients who did not achieve improvement of glycemic control [10]. However, in this study, diabetic patients had other complications that may have affected left ventricular mass independently of diabetes. Indeed, it is known that retinopathy and nephropathy, associated with type 1 diabetes, can also affect myocardial remodeling [11]. In this regard, studies conducted in individuals with uncomplicated type 1 diabetes did not detect LVH [12,13].

Interstitial fibrosis

Diabetic cardiomyopathy is characterized by interstitial fibrosis, mainly composed of collagen, and perivascular fibrosis. Regan et al [14] found a significant increase in deposition of collagen around the vessel and between the myofibers in heart biopsies from diabetic patients. In addition, a significant increase in collagen type III, but not type I or VI, was found in endomyocardial biopsies obtained from patients with type 2 diabetes, free of CAD and hypertension [15]. Furthermore, diastolic dysfunction detected in a population of patients with uncomplicated type 2 diabetes correlated with pro-collagen type I carboxy-terminal peptide [16], suggesting a mechanistic involvement of myocardial fibrosis in the myocardial dysfunction that occurs in diabetes.

Increased cell death and oxidative stress

Diabetes is associated with myocyte cell death; however, it is unclear whether diabetes can directly activate cell death or, rather, it activates pathways known to induce this process. Indeed, activation of the renin-angiotensin system (RAS) was associated with increased oxidative stress and cardiomyocyte and endothelial cell death in hearts of patients with diabetes [17,18]. Thus inhibition of the RAS reduced the rate of first admission

to hospital from heart failure and improved echocardiographic indices of left ventricular diastolic function in patients with type 2 diabetes [19,20]. The mechanisms by which cell death occurs in the human myocardium are still not well understood. Thus, where both forms of cell death (necrosis and apoptosis) were identified in myocardium biopsies of patients with diabetes, apoptosis was maximally induced in the diabetic myocardium, whereas necrosis was exaggerated by hypertension [17]. Recently, Chowdhry et al [21] showed that apoptosis and necrosis were increased in the right atrial appendage of patients with type 1 and type 2 diabetes, and that inhibition of caspase-3 reduced apoptosis without influencing necrosis, whereas inhibition of poly-adenosine diphosphate-ribose polymerase reduced necrosis and apoptosis. Although the findings of previous studies have implied that oxidative stress may have a critical role in the development of DCM, this issue has not been properly and fully addressed in humans. The majority of reactive oxygen species (ROS) are generated in the mitochondria. However, enzymatic systems capable of generating ROS in the cytosol – such as NADPH oxidase – can be modulated by hyperglycemia [22]. ROS can also interact with nitric oxide to form nitrotyrosine, which was found to be increased in myocardial biopsies of humans with type 2 diabetes [17]. Finally, studies of the role of antioxidants in preventing cardiac dysfunction in humans have been disappointing. Indeed, in a randomized controlled trial in patients receiving vitamin E, the risk of heart failure was greater in patients receiving the antioxidant treatment [23].

Myocardial lipotoxicity

Diabetic myocardium is also characterized by increased deposition of intramyocardial lipids, which can contribute to cell death and thus to cardiac dysfunction. Regan et al [14] identified deposits of lipofuscin, which are brown pigment granules composed of lipid-containing residues, in left ventricular transmural biopsies obtained from diabetic patients. Furthermore, they measured myocardial triglyceride and cholesterol content in these biopsies and found a significant increase. Similarly, Oil Red O staining of heart sections of non ischemic failing hearts revealed an increased deposition of lipid that was exacerbated by diabetes [24]. More importantly, increased myocardial triglyceride in patients with type 2 diabetes was associated with diastolic, but not systolic, dysfunction [25].

Functional changes

In the course of DCM, several functional changes develop and progress (*Figure 1*). It is therefore incumbent upon clinicians to identify these abnormalities,

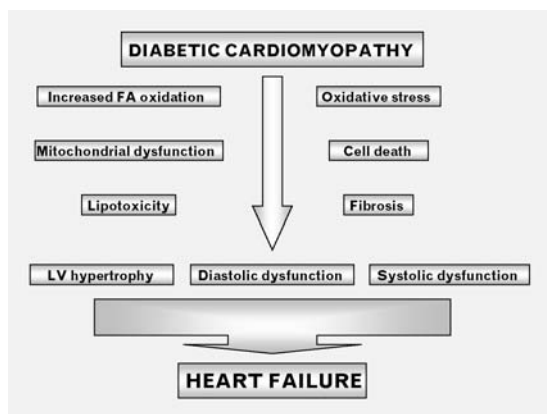


Figure 1. Abnormalities associated with diabetic cardiomyopathy. FA, fatty acid; LV, left ventricular.

because early detection and appropriate treatment can prevent worsening of this condition to overt heart failure.

Diastolic dysfunction

Diabetic cardiomyopathy in humans is characterized by diastolic dysfunction, which may precede the development of systolic dysfunction. Indeed, echocardiography performed in 87 patients with type 1 diabetes mellitus without known CAD revealed diastolic dysfunction as indicated by reduced early diastolic filling, increased atrial filling, extended isovolumetric relaxation, and increased supraventricular premature beats [26]. Similarly, in individuals with uncomplicated type 1 diabetes without clinically apparent macrovascular or microvascular complications, Carugo et al [27] reported an age-related increase in diastolic diameter. Similar approaches in patients with well controlled type 2 diabetes revealed a prevalence of diastolic dysfunction in up to 30% [28,29]. The use of flow and tissue Doppler techniques suggests an even greater prevalence of diastolic dysfunction (as much as 40–75%) in individuals with type 1 and type 2 diabetes without overt CAD [30,31]. Indeed, indices for diastolic dysfunction such as E/E' and E/A' ratios (where E is the flow related to early ventricular filling and E' and A' are early and late diastolic velocities, respectively) were impaired in patients with type 2 diabetes [32,33].

Systolic dysfunction

In the context of DCM, systolic dysfunction occurs late, often when patients have already developed significant diastolic dysfunction. Thus, in a population of patients with type 1 diabetes with several degree of complications, systolic dysfunction was observed in 39% of those with complications and in only 6% of those free from complications [34]. In addition, a subtle systolic dysfunction, which is usually charac-

terized by a low left ventricular ejection fraction (LVEF), is often missed when standard 2-dimensional echocardiography techniques are used. Thus studies have emerged that demonstrate subtle abnormalities in systolic function in association with a diagnosis of diastolic dysfunction [35,36]. In a well defined study population of relatively young persons with long-term type 1 diabetes, reduced left ventricular compliance, increased afterload, and decreased myocardial contractility were observed [37]. In contrast, a study performed in young patients with type 1 diabetes showed that myocardial contractility was not depressed, but rather exaggerated [9]. Similarly, in a recent study of patients with type 1 diabetes, myocardial dysfunction was absent despite changes in the structure of the heart [38]. It is important to note that the patients in this study were treated four to five times daily with insulin, which may have prevented contractile dysfunction.

Impaired contractile reserve

Diabetic cardiomyopathy involves several stages of disease, including a period in which symptoms are not present, and resting left ventricular dimension and function are still normal. In this early phase, left ventricular dysfunction can be characterized by exercise. Indeed, impaired augmentation of LVEF occurs in as many as 40% of patients with diabetes [39]. Recent reports in both type 1 and type 2 diabetes showed that longitudinal functional reserve (indicated by reduced mitral annular systolic and early diastolic velocities) and left ventricular contractility reserve (indicated by depressed peak exercise left ventricular stroke index, cardiac index, and LVEF) were reduced after exercise [13,40], whereas no change in these parameters was observed at rest. Thus cardiac performance after exercise could be a tool with which to detect early contractile dysfunction in diabetes.

Metabolic changes

Studies of altered cardiac metabolism in animal models of diabetes have emerged in recent years, becoming an attractive mechanism contributing to the development of DCM. In this section, we will discuss the recent findings supporting the existence of altered cardiac substrate metabolism and mitochondrial dysfunction in the heart of humans with diabetes.

Altered substrate utilization

The main characteristic of diabetes is an increase in serum glucose and free fatty acid (FFA) concentrations. Thus the diabetic heart relies almost

completely on FFA utilization. This is in part a result of decreased cardiac uptake of glucose, caused by either insulin resistance or depressed transcription of glucose transporters. Indeed, glucose transporter 4 transcript and its regulator, the myocyte enhancer factor 2C, were significantly downregulated in failing hearts of patients with diabetes as opposed to failing hearts in those without diabetes [41]. In addition, reduced cardiac glucose uptake was observed both in type 2 [42] and type 1 [43] diabetic patients, although in another study it was reported to be unchanged in patients with type 2 diabetes [44]. These differences come from the presence or absence of hypertriglyceridemia, which is known to contribute to cardiac lipotoxicity and thus affect insulin-stimulated cardiac uptake of glucose. Similarly, in obese insulin-resistant women, neither cardiac glucose uptake nor myocardial glucose utilization was altered, whereas increased fatty acid oxidation and myocardial oxygen consumption (mVO_2) and reduced cardiac efficiency were observed [45]. Cardiac efficiency was inversely associated with insulin resistance, glucose intolerance, and obesity. It is likely that these changes may contribute to the pathogenesis of decreased cardiac performance in obesity and insulin-resistant states. Similarly, studies of patients with type 1 diabetes revealed increased myocardial use of fatty acids and reduced glucose oxidation [46]. Altered metabolism in these patients was associated with increased mVO_2 and increased concentrations of serum FFA. The mechanism for increased fatty acid oxidation in the myocardium of diabetic humans is not fully understood, but may involve transcriptional regulation of key components of this pathway. Indeed, Sharma et al [24] showed that diabetes increased the mRNA level of mitochondrial carnitine palmitoyl-transferase 1, an enzyme involved in mitochondrial fatty acid uptake, in human hearts. Thus it will be important in future studies to determine whether therapies that will correct abnormal myocardial substrate metabolism in diabetes mellitus will translate to a reduced prevalence of heart failure or improved long-term survival.

Mitochondrial dysfunction

In contrast to skeletal muscle, studies examining mitochondrial function in cardiac muscle of diabetic patients have been challenging. Our contribution to the understanding of mitochondrial bioenergetics comes mainly from animal studies of obesity and diabetes [47]. Reagan et al [14] first reported increased numbers of mitochondria with pleomorphism, but no swelling or evident distortion of cristae in the myocardium of patients with diabetes. Using phosphorus-31 nuclear resonance spectroscopy,

Clarke's group provided evidence for decreased cardiac energetics in patients with type 2 diabetes who were free from CAD [48]. Although no direct measure of mitochondrial capacity was provided in this study, mitochondrial generation of ATP was reduced with diabetes, as indicated by the reduction in phosphocreatine/ATP ratios. Finally, studies related to the response of the diabetic heart to ischemic preconditioning have suggested that a defect in the mitochondrial ATP-sensitive potassium channel could explain the inability of the diabetic myocardium to respond to ischemic preconditioning and increase the risk for myocardial infarction [49].

Conclusion

The belief is widely held that the increase in cardiovascular mortality is a consequence of accelerated atherosclerosis. However, compelling epidemiological and clinical data indicate that diabetes mellitus increases the risk for cardiac dysfunction and heart failure independently of other risk factors such as CAD and hypertension. Thus DCM has become a well characterized clinical disease that is manifested by structural, functional, and metabolic changes. It is hoped that, as the mechanisms responsible for DCM continue to be elucidated, they will provide the impetus for generating novel therapies tailored to reduce the risk of heart failure in individuals with diabetes mellitus.

*See glossary for definition of this term. ■

REFERENCES

1. Rubler S, Dlugash J, Yuceoglu YZ, Kumral T, Branwood AW, Grishman A. New type of cardiomyopathy associated with diabetic glomerulosclerosis. *Am J Cardiol.* 1972;30:595–602.
2. Hayat SA, Patel B, Khattar RS, Malik RA. Diabetic cardiomyopathy: mechanisms, diagnosis and treatment. *Clin Sci (Lond).* 2004;107:539–557.
3. Aneja A, Tang WH, Bansilal S, Garcia MJ, Farkouh ME. Diabetic cardiomyopathy: insights into pathogenesis, diagnostic challenges, and therapeutic options. *Am J Med.* 2008;121:748–757.
4. Galderisi M, Anderson KM, Wilson PW, Levy D. Echocardiographic evidence for the existence of a distinct diabetic cardiomyopathy (the Framingham Heart Study). *Am J Cardiol.* 1991;68:85–89.
5. Lieb W, Xanthakis V, Sullivan LM, et al. Longitudinal tracking of left ventricular mass over the adult life course: clinical correlates of short- and long-term change in the Framingham Offspring Study. *Circulation.* 2009;119:3085–3092.
6. Devereux RB, Roman MJ, Paranicas M, et al. Impact of diabetes on cardiac structure and function: the Strong Heart Study. *Circulation.* 2000;101:2271–2276.
7. Eguchi K, Boden-Albala B, Jin Z, et al. Association between diabetes mellitus and left ventricular hypertrophy in a multi-ethnic population. *Am J Cardiol.* 2008;101:1787–1791.
8. Rerkpattanapipat P, D'Agostino RB Jr, Link KM, et al. Location of arterial stiffening differs in those with impaired fasting glucose versus diabetes: implications for left ventricular hypertrophy from the Multi-Ethnic Study of Atherosclerosis. *Diabetes.* 2009;58:946–953.

9. Airaksinen KE, Ikaheimo MJ, Linnaluoto MK, Huikuri HV, Takkunen JT. Increased left atrial size relative to left ventricular size in young women with insulin-dependent diabetes: a pre-clinical sign of the specific heart disease of diabetes? *Diabetes Res.* 1987;6:37–41.
10. Aepfelbacher FC, Yeon SB, Weinrauch LA, D'Elia J, Burger AJ. Improved glycemic control induces regression of left ventricular mass in patients with type 1 diabetes mellitus. *Int J Cardiol.* 2004;94:47–51.
11. Cheung N, Bluemke DA, Klein R, et al. Retinal arteriolar narrowing and left ventricular remodeling: the multi-ethnic study of atherosclerosis. *J Am Coll Cardiol.* 2007;50:48–55.
12. Huikuri HV, Airaksinen JK, Lilja M, Takkunen JT. Echocardiographic evaluation of left ventricular response to isometric exercise in young insulin-dependent diabetics. *Acta Diabetol Lat.* 1986;23:193–200.
13. Palmieri V, Capaldo B, Russo C, et al. Uncomplicated type 1 diabetes and preclinical left ventricular myocardial dysfunction: insights from echocardiography and exercise cardiac performance evaluation. *Diabetes Res Clin Pract.* 2008;79:262–268.
14. Regan TJ, Lyons MM, Ahmed SS, et al. Evidence for cardiomyopathy in familial diabetes mellitus. *J Clin Invest.* 1977;60:884–899.
15. Shimizu M, Umeda K, Sugihara N, et al. Collagen remodelling in myocardia of patients with diabetes. *J Clin Pathol.* 1993;46:32–36.
16. Gonzalez-Vilchez F, Ayuela J, Ares M, Pi J, Castillo L, Martín-Durán R. Oxidative stress and fibrosis in incipient myocardial dysfunction in type 2 diabetic patients. *Int J Cardiol.* 2005;101:53–58.
17. Frustaci A, Kajstura J, Chimenti C, et al. Myocardial cell death in human diabetes. *Circ Res.* 2000;87:1123–1132.
18. Dhalla NS, Liu X, Panagia V, Takeda N. Subcellular remodeling and heart dysfunction in chronic diabetes. *Cardiovasc Res.* 1998;40:239–247.
19. Brenner BM, Cooper ME, de Zeeuw D, et al., the RENAAL Study Investigators. Effects of losartan on renal and cardiovascular outcomes in patients with type 2 diabetes and nephropathy. *N Engl J Med.* 2001;345:861–869.
20. Symeonides P, Koulouris S, Vratisista E, et al. Both ramipril and telmisartan reverse indices of early diabetic cardiomyopathy: a comparative study. *Eur J Echocardiogr.* 2007;8:480–486.
21. Chowdhry MF, Vohra HA, Galinanes M. Diabetes increases apoptosis and necrosis in both ischemic and nonischemic human myocardium: role of caspases and poly-adenosine diphosphate-ribose polymerase. *J Thorac Cardiovasc Surg.* 2007;134:124–131; 131.e1–3.
22. Li L, Renier G. Activation of nicotinamide adenine dinucleotide phosphate (reduced form) oxidase by advanced glycation end products links oxidative stress to altered retinal vascular endothelial growth factor expression. *Metab Clin Exp.* 2006;55:1516–1523.
23. Lonn E, Bosch J, Yusuf S, et al., the HOPE and HOPE-TOO Trial Investigators. Effects of long-term vitamin E supplementation on cardiovascular events and cancer: a randomized controlled trial. *JAMA.* 2005;293:1338–1347.
24. Sharma S, Adrogue JV, Golfman L, et al. Intramyocardial lipid accumulation in the failing human heart resembles the lipotoxic rat heart. *Faseb J.* 2004;18:1692–1700.
25. Rijzewijk LJ, van der Meer RW, Smit JW, et al. Myocardial steatosis is an independent predictor of diastolic dysfunction in type 2 diabetes mellitus. *J Am Coll Cardiol.* 2008;52:1793–1799.
26. Schannwell CM, Schneppenheim M, Perings S, Plehn G, Strauer BE. Left ventricular diastolic dysfunction as an early manifestation of diabetic cardiomyopathy. *Cardiology.* 2002;98:33–39.
27. Carugo S, Giannattasio C, Calchera I, et al. Progression of functional and structural cardiac alterations in young normotensive uncomplicated patients with type 1 diabetes mellitus. *J Hypertens.* 2001;19:1675–1680.
28. Beljic T, Miric M. Improved metabolic control does not reverse left ventricular filling abnormalities in newly diagnosed non-insulin-dependent diabetes patients. *Acta Diabetol.* 1994;31:147–150.
29. Di Bonito P, Cuomo S, Moio N, et al. Diastolic dysfunction in patients with non-insulin-dependent diabetes mellitus of short duration. *Diabet Med.* 1996;13:321–324.
30. Boyer JK, Thanigaraj S, Schechtman KB, Pérez JE. Prevalence of ventricular diastolic dysfunction in asymptomatic, normotensive patients with diabetes mellitus. *Am J Cardiol.* 2004;93:870–875.
31. Shivalkar B, Dhondt D, Goovaerts I, et al. Flow mediated dilatation and cardiac function in type 1 diabetes mellitus. *Am J Cardiol.* 2006;97:77–82.
32. Brooks BA, Franjic B, Ban CR, et al. Diastolic dysfunction and abnormalities of the microcirculation in type 2 diabetes. *Diabetes Obes Metab.* 2008;10:739–746.
33. Ozasa N, Furukawa Y, Morimoto T, Tadamura E, Kita T, Kimura T. Relation among left ventricular mass, insulin resistance, and hemodynamic parameters in type 2 diabetes. *Hypertens Res.* 2008;31:425–432.
34. Raev DC. Left ventricular function and specific diabetic complications in other target organs in young insulin-dependent diabetics: an echocardiographic study. *Heart Vessels.* 1994;9:121–128.
35. Yu CM, Lin H, Yang H, Kong SL, Zhang Q, Lee SW. Progression of systolic abnormalities in patients with “isolated” diastolic heart failure and diastolic dysfunction. *Circulation.* 2002;105:1195–1201.
36. Fang ZY, Schull-Meade R, Leano R, Mottram PM, Prins JB, Marwick TH. Screening for heart disease in diabetic subjects. *Am Heart J.* 2005;149:349–354.
37. Danielsen R, Nordrehaug JE, Lien E, Vik-Mo H. Subclinical left ventricular abnormalities in young subjects with long-term type 1 diabetes mellitus detected by digitized M-mode echocardiography. *Am J Cardiol.* 1987;60:143–146.
38. Konduracka E, Gackowski A, Rostoff P, Galicka-Latala D, Frasik W, Piwowarska W. Diabetes-specific cardiomyopathy in type 1 diabetes mellitus: no evidence for its occurrence in the era of intensive insulin therapy. *Eur Heart J.* 2007;28:2465–2471.
39. Scognamiglio R, Avogaro A, Casara D, et al. Myocardial dysfunction and adrenergic cardiac innervation in patients with insulin-dependent diabetes mellitus. *J Am Coll Cardiol.* 1998;31:404–412.
40. Ha JW, Lee HC, Kang ES, et al. Abnormal left ventricular longitudinal functional reserve in patients with diabetes mellitus: implication for detecting subclinical myocardial dysfunction using exercise tissue Doppler echocardiography. *Heart.* 2007;93:1571–1576.
41. Razeghi P, Young ME, Cockrill TC, Frazier OH, Taegtmeier H. Downregulation of myocardial myocyte enhancer factor 2C and myocyte enhancer factor 2C-regulated gene expression in diabetic patients with nonischemic heart failure. *Circulation.* 2002;106:407–411.
42. Monti LD, Landoni C, Setola E, et al. Myocardial insulin resistance associated with chronic hypertriglyceridemia and increased FFA levels in type 2 diabetic patients. *Am J Physiol Heart Circ Physiol.* 2004;287:H1225–H1231.
43. Doria A, Nosadini R, Avogaro A, Fioretto P, Crepaldi G. Myocardial metabolism in type 1 diabetic patients without coronary artery disease. *Diabet Med.* 1991; 8 Spec No:S104–S107.
44. Utriainen T, Takala T, Luotolahti M, et al. Insulin resistance characterizes glucose uptake in skeletal muscle but not in the heart in NIDDM. *Diabetologia.* 1998;41:555–559.
45. Peterson LR, Herrero P, Schechtman KB, et al. Effect of obesity and insulin resistance on myocardial substrate metabolism and efficiency in young women. *Circulation.* 2004;109:2191–2196.
46. Herrero P, Peterson LR, McGill JB, et al. Increased myocardial fatty acid metabolism in patients with type 1 diabetes mellitus. *J Am Coll Cardiol.* 2006;47:598–604.
47. Boudina S, Abel ED. Diabetic cardiomyopathy revisited. *Circulation.* 2007;115:3213–3223.
48. Scheuermann-Freestone M, Madsen PL, Manners D, et al. Abnormal cardiac and skeletal muscle energy metabolism in patients with type 2 diabetes. *Circulation.* 2003;107:3040–3046.
49. Hassouna A, Loubani M, Matata BM, Fowler A, Standen NB, Galiñanes M. Mitochondrial dysfunction as the cause of the failure to precondition the diabetic human myocardium. *Cardiovasc Res.* 2006;69:450–458.