Heart Metab. (2016) 71:27-31

HFpEF or just multiple comorbidities? The challenges of making a definitive diagnosis

Jessica Webb, BM BCh, MA, MRCP, FHEA
Division of Imaging Sciences and Biomedical Engineering, King's College London, SE1 7EH, UK; Department of Cardiology, Princess Royal University Hospital, BR6 8ND, UK

Correspondence: Dr Jessica Webb, Division of Imaging Sciences and Biomedical Engineering, 4th floor Lambeth Wing, King's College London, SE1 7EH, UK
E-mail: Jessica.webb@kcl.ac.uk

Abstract

Heart failure is a complex clinical syndrome resulting from the inability of the heart to meet the metabolic needs of the body at normal ventricular filling pressures. The clinical manifestations are breathlessness, fatigue, and fluid retention. It is a progressive disease, characterized by high rates of hospitalization that tend to increase over time. Studies have suggested that approximately half of the estimated 1 million people with heart failure in the United Kingdom have heart failure with preserved ejection fraction (HFpEF). Imaging is clearly critical in identifying patients with heart failure symptoms and a normal ejection fraction, although imaging parameters of diastolic dysfunction do not always correlate with the gold standard diagnostic test, invasive pressure-volume loop analysis. The updated 2016 European Society of Cardiology (ESC) guidelines have simplified the diagnosis of HFpEF; nevertheless, diagnosis remains challenging in patients with multiple comorbidities. As this case report highlights, there is an unmet need for access to advanced imaging techniques to accurately identify these patients. ■ *Heart Metab*. 2016;71:27-31

Keywords: cardiac magnetic resonance imaging; HFpEF; pressure-volume loop analysis

A 71-year-old Afro-Caribbean woman was seen in the heart failure clinic with shortness of breath (New York Heart Association functional class III) and fatigue. She was known to have long-standing hypertension, diabetes, mild chronic obstructive pulmonary disease (she was an ex smoker), obstructive sleep apnea (OSA), and bilateral adrenal nodules.

Three years previously, this patient had a coronary angiogram that confirmed unobstructed coronary arteries, and a Reveal device was inserted, which did not detect any malignant arrhythmias. This patient, reviewed by the hypertension service and thought not to have Conn syndrome, was advised to continue her antihypertensive medications. Two years later, the patient was admitted with pulmonary edema, hypertension, and acute kidney injury. Then, three months before the latest visit, the patient was admitted to hospital to treat her edema and to rationalize her medications, as she was suffering with postural hypotension and deranged electrolytes. Since that admission, the patient's symptoms deteriorated and she began waking every hour during sleep, struggling to

Heart Metab. (2016) 71:27-31

Abbreviations

BMI: body mass index; **BNP:** B-type natriuretic peptide; **COPD:** chronic obstructive pulmonary disease; **EDPVR:** end-diastolic pressure-volume relationship; **HFpEF:** heart failure with preserved ejection fraction; **LV:** left ventricular; **LVEF:** left ventricular ejection fraction; **OSA:** obstructive sleep apnea

use her continuous positive airway pressure (CPAP) machine, and sleeping with two pillows. In addition, she complained of generalized body pains, a poor appetite, and presyncope on standing, which was associated with palpitations lasting up to 30 seconds. There were no episodes of loss of consciousness.

On her most recent examination, her weight was 80.2 kg, her height was 152 cm, and her body mass index (BMI) was 34.7 kg/m^2. Her pulse was 60 beats per minute and regular, with a supine blood pressure of 160/80 mm Hg and a standing blood pressure of 140/80 mm Hg. There was no peripheral edema, her jugular venous pressure (JVP) was not raised, and auscultation of her chest confirmed vesicular breath sounds with air entry equal bilaterally.

This patient's medications included bisoprolol 10 mg, nifedipine 20 mg, and frusemide 20 mg, taken at 8AM and at 12 noon. In addition, she took warfarin, gliclazide, simvastatin, co-codamol, and used asthma inhalers (tiotropium, salbutamol). She was intolerant of angiotensin-converting enzyme (ACE) inhibitors.

The electrocardiogram showed sinus rhythm with left bundle branch block and a QRS duration of 126 ms. Blood analysis confirmed an elevated N-terminal pro–B-type natriuretic peptide level (NT-proBNP; 2439 ng/L), stage 4 renal dysfunction (glomerular filtration rate [GFR], 20 mL/min), and associated anemia (hemoglobin level, 93 g/L). Sodium and potassium were both within normal limits. Echocardiography confirmed preserved biventricular systolic function with normal left ventricular (LV) size. There was severe concentric remodeling (LV hypertrophy) and left atrial enlargement with grade 1 diastolic dysfunction (*Figure 1*). These findings are consistent with increased LV filling pressures. The lateral e' velocity was 4.5 cm/s and E/e' was 20. Longitudinal right ventricular function was normal, and there was mild tricuspid regurgitation (TR velocity, 3.15 m/s) with an estimated pulmonary artery systolic pressure (PASP) of 40 mm Hg.

Cardiac magnetic resonance (CMR) imaging was performed and confirmed normal LV volumes and a mildly reduced LV ejection fraction (LVEF, 55%). There was increased LV wall mass with increased wall thickness, maximal in the mid septal segment at 21 mm (*Figure 2A*). The left atrial size was 26 cm^2 (*Figure 2B*). After the administration of gadolinium, there was no late enhancement, and native T1 (longitudinal relaxation time) was increased at 1118.3 ms (normal range in the 1.5-Tesla scanner, 900-1000 ms).

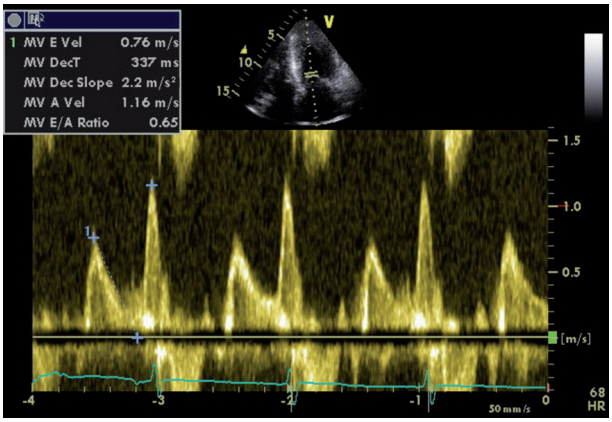

Fig. 1 *Mitral valve pulse wave Doppler confirming grade 1 diastolic dysfunction.*
Abbreviations: *DecT, deceleration time; Dec Slope, deceleration slope; E/A ratio, ratio of peak early to late diastolic velocities; E Vel, E velocity; HR, heart rate; MV, mitral valve.*

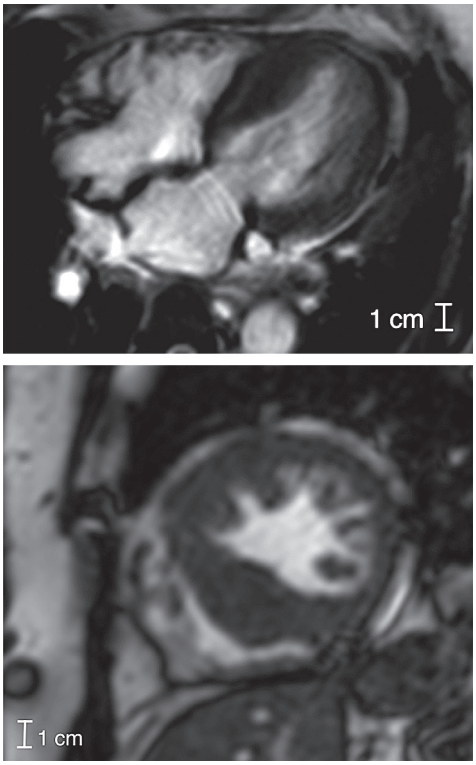

Fig. 2 (A) *Cardiac magnetic resonance imaging of the mid left ventricle (short axis) showing increased left ventricular wall thickness.* ***(B)*** *Cardiac magnetic resonance imaging four-chamber view showing increased left ventricular wall thickness and mildly enlarged left atrial size.*

Discussion

This elderly Afro-Caribbean patient has multiple comorbidities: hypertension, diabetes, OSA, and chronic obstructive pulmonary disorder, and has had admissions with heart failure in the context of a normal LV size and mildly impaired LV dysfunction. The diagnosis of heart failure with preserved ejection fraction (HFpEF) is challenging in the elderly, as signs and symptoms are often nonspecific, although it is the most likely unifying diagnosis in this patient. Practically, clinicians rely on echocardiographic measures of diastolic dysfunction to assist in making this diagnosis, and according to the recent American Society of Echocardiography/European Association of Cardiovascular Imaging (ASE/EACVI) guidelines, this patient has definite diastolic dysfunction (the patient has more than two of the four requirements, which are average E/e' >14, lateral e' velocity <10 cm/s, TR velocity >2.8 m/s, and left atrial volume index >34 mL/m^2).[1] The newly updated 2016 European Society of Cardiology (ESC) guidelines on the diagnosis of heart failure with preserved ejection fraction (HFpEF)[2] have separated HFpEF from heart failure with middle-range LV ejection function in the hope of simplifying the diagnostic process. The current guidelines recommend that the following four conditions must be satisfied to diagnose HFpEF: presence of symptoms and signs typical of heart failure, LVEF >50%, elevated biomarkers, and either structural (left atrial enlargement >34 mL/m^2 or LV mass index >115 g/m^2 in males or >95 g/m^2 in females) or functional changes (average E/e' >13 or average e' velocity <9 cm/s). The 2013 American College of Cardiology/American Heart Association (ACC/AHA) consensus statement based the diagnosis of HFpEF on typical symptoms and signs of heart failure in a patient with a normal or near normal LVEF and no significant valvular abnormalities detected by echocardiography.[3] Thus, by both diagnostic criteria, this patient has HFpEF.

The exact pathophysiology of HFpEF remains uncertain, although increased LV passive stiffness is consistently reported.[4,5] Patients often have overlapping comorbidities, and it has only recently been convincingly demonstrated that HFpEF represents more than a sum of all its comorbidities and is a condition in its own right.[6,7] HFpEF is probably caused by a combination of the following: (i) diastolic dysfunction; (ii) impaired systolic function on exercise; (iii) abnormal ventricular-arterial coupling; (iv) inflammation and endothelial dysfunction; (v) chronotropic incompetence; (vi) altered myocardial and peripheral skeletal muscle metabolism and perfusion; (vii) pulmonary hypertension; and (viii) renal insufficiency.[5]

It has recently been proposed that within the heterogeneous HFpEF population there are three distinct phenogroups.[8] Using unbiased hierarchical clustering analysis of phenotypical data and penalized model-based clustering, it has been possible for Shah et al[8] to categorize patients who were identified via the following criteria: having received a diagnosis of heart failure, the presence of the words "heart failure" in the discharge notes, having a B-type natriuretic peptide (BNP) level >100 pg/mL, or having received more than two doses of intravenous diuretics. Following discharge, patients needed to have an LVEF >50%, significant diastolic dysfunction (grade 2 or 3) on echocardiography, evidence of elevated LV filling pressures on invasive hemodynamic testing (demonstrating increased LV filling pressures), or a BNP level >100 pg/mL. Phenogroup 2 is described as having the highest prevalence of obesity, diabetes, hypertension, OSA, and the worst LV relaxation (defined as lower e' velocities); phenogroup 3 is described as being elderly with chronic kidney disease (CKD), having the highest BNP levels, and having more severe electrical and myocardial remodeling. This patient does not fit neatly into either phenogroup 2 or 3 and is best described as lying between the two. It remains to be seen how clinically useful these phenogroups are and if clustering can be used to predict outcome or response to therapy. Previous large epidemiological studies have found that HFpEF patients are more likely to be older females with a history of hypertension, diabetes mellitus, atrial fibrillation, and coronary artery disease[9-11]; also, renal impairment, chronic lung disease, liver disease, hypothyroidism, and anemia have been reported in the HFpEF population.[12] In addition, it has recently been suggested that there are different geographical populations of HFpEF, which further contributes to the challenges in accurately diagnosing HFpEF.[5] Despite this, Shah's phenogroup-based classification represents a significant development in understanding the HFpEF population, but further work is needed to ensure that it is universally applicable.

As part of this patient's assessment, she was referred for invasive pressure-volume studies, which are

Heart Metab. (2016) 71:27-31

considered the gold standard for HFpEF diagnosis. Burkhoff et al provide an overview of the principles behind such analysis,[13] summarized here. The LV end-diastolic pressure-volume relationship (EDPVR) defines the passive physical properties of the LV chamber and reflects the net effects of all facets of myocardial material properties, chamber structural properties, and the extracellular matrix. Changes in EDPVR may reflect myocardial fibrosis, ischemia, and edema, or they may be caused by physiological (normal growth) or pathological (hypertrophy, chamber enlargement) remodeling. In the low pressure-volume range, there is only a small increase in pressure for a given increment in volume. The stiffness is thought to be due to compliant elastin fibers and stretched myocytes constrained by sarcomeric titin. With further volume increases, the pressure rises more steeply as stretch is resisted by the stiff elements (the slack lengths of collagen fibers and titin are exceeded). Because the EDPVR is nonlinear, the chamber stiffness varies with filling pressures. The chamber-stiffness constant, β (1/mL), allows diastolic chamber properties to be indexed; by multiplying β by LV wall volume (V_w), a dimensionless chamber-stiffness index is obtained (β_w). This allows different heart sizes to be compared. In addition, elastance can be measured, which is defined as the change in pressure for a given change in volume within a chamber. So, the higher the elastance, the stiffer the chamber wall. Patients with HFpEF have a prolonged tau (τ), which is the isovolumic relaxation constant. In 2007, Kasner et al investigated 43 clinically symptomatic patients; diastolic dysfunction was considered present if τ was prolonged (>48 ms), the LV end-diastolic pressure (LVEDP) was elevated (>12 mm Hg), and/or β was elevated (>0.015 mL^{-1}) despite normal ejection fraction.[14] These cutoff values were defined as values corresponding to the 90th percentiles of their control patients. According to these criteria and on the basis of the pressure-volume study, our patient has diastolic dysfunction. *Figure 3* shows the pressure-volume loops for baseline readings (red loop) and reduced preload and afterload readings (blue loop), with minimal change shown for leg raise (increased preload).

There are still many challenges in managing patients with HFpEF, not least because there are no current treatments, and patients have multiple comorbidities that can make imaging challenging (poor acoustic windows due to increased BMI, and for CMR difficulty with breath holding, atrial fibrillation, and raised BMI). Moreover, it is not always appropriate to send all patients to the catheter laboratory for invasive pressure-volume studies. Nonetheless, as illustrated by this case, it does provide further assurance of diagnosis based on noninvasive imaging. ■

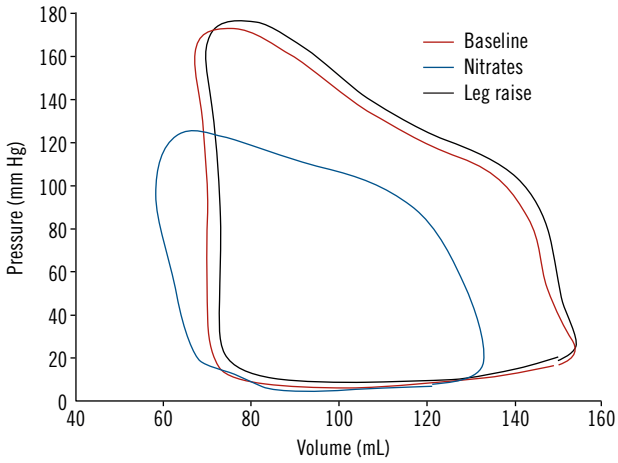

Fig. 3 *Pressure-volume loops with changing preload. The red loop shows baseline readings; the blue loop shows readings after treatment with nitrates, a preload- and afterload-reducing drug; and the black loop shows readings with leg raise. Pressures and volumes are reduced with nitrates. Load-independent measurements of relaxation confirm heart failure with preserved ejection fraction (HFpEF). See text for additional details.*

REFERENCES

1. Nagueh SF, Smiseth OA, Appleton CP, et al. Recommendations for the evaluation of left ventricular diastolic function by echocardiography: an update from the American Society of Echocardiography and the European Association of Cardiovascular Imaging. *J Am Soc Echocardiogr*. 2016;29(4):277-314.
2. Ponikowski P, Voors AA, Anker SD, et al; Authors/Task Force Members. 2016 ESC Guidelines for the diagnosis and treatment of acute and chronic heart failure: the Task Force for the Diagnosis and Treatment of Acute and Chronic Heart Failure of the European Society of Cardiology (ESC). Developed with the special contribution of the Heart Failure Association (HFA) of the ESC. *Eur Heart J*. 2016;37(27):2129-2200.
3. Yancy CW, Jessup M, Bozkurt B, et al; American College of Cardiology Foundation; American Heart Association Task Force on Practice Guidelines. 2013 ACCF/AHA Guideline for the management of heart failure: a report of the American College of Cardiology Foundation/American Heart Association Task Force on Practice Guidelines. *J Am Coll Cardiol*. 2013;62(16):e147-e239.
4. Zile MR, Baicu CF, Gaasch WH. Diastolic heart failure—abnormalities in active relaxation and passive stiffness of the left ventricle. *N Engl J Med*. 2004;350(19):1953-1959.
5. Sharma K, Kass DA. Heart failure with preserved ejection fraction: mechanisms, clinical features, and therapies. *Circ Res*. 2014;115(1):79-96.
6. Mohammed SF, Borlaug BA, Roger VL, et al. Comorbidity and ventricular and vascular structure and function in heart failure with preserved ejection fraction: a community-based study.

Circ Heart Fail. 2012;5(6):710-719.
7. Campbell RT, Jhund PS, Castagno D, Hawkins NM, Petrie MC, McMurray JJ. What have we learned about patients with heart failure and preserved ejection fraction from DIG-PEF, CHARM-preserved, and I-PRESERVE? *J Am Coll Cardiol*. 2012;60(23):2349-2356.
8. Shah SJ, Katz DH, Selvaraj S, et al. Phenomapping for novel classification of heart failure with preserved ejection fraction. *Circulation*. 2015;131(3):269-279.
9. Lenzen MJ, Scholte op Reimer WJ, Boersma E, et al. Differences between patients with a preserved and a depressed left ventricular function: a report from the EuroHeart Failure Survey. *Eur Heart J*. 2004;25(14):1214-1220.
10. Owan TE, Hodge DO, Herges RM, Jacobsen SJ, Roger VL, Redfield MM. Trends in prevalence and outcome of heart failure with preserved ejection fraction. *N Engl J Med*. 2006;355(3):251-259.
11. Bhatia RS, Tu JV, Lee DS, et al. Outcome of heart failure with preserved ejection fraction in a population-based study. *N Engl J Med*. 2006;355(3):260-269.
12. Lam CS, Donal E, Kraigher-Krainer E, Vasan RS. Epidemiology and clinical course of heart failure with preserved ejection fraction. *Eur J Heart Fail*. 2011;13(1):18-28.
13. Burkhoff D, Mirsky I, Suga H. Assessment of systolic and diastolic ventricular properties via pressure-volume analysis: a guide for clinical, translational, and basic researchers. *Am J Physiol Heart Circ Physiol*. 2005;289(2):H501-H512.
14. Kasner M, Westermann D, Steendijk P, et al. Utility of Doppler echocardiography and tissue Doppler imaging in the estimation of diastolic function in heart failure with normal ejection fraction: a comparative Doppler-conductance catheterization study. *Circulation*. 2007;116(6):637-647.